

MARPE(Miniscrew-assisted Rapid Palatal Expansion) treatment of Dental Class II malocclusion with Horizontal discrepancy and multiple teeth missing : A Case Report.

Mi Young Lee
Seoul National University Gwan-ak Dental Hospital

Introduction

Horizontal discrepancy was some times overlooked in orthodontic treatment because it was difficult for patients to recognize and often unrelated to aesthetic reasons. However, if horizontal discrepancy was not treated, it was difficult to obtain reasonable results. With the development of orthodontic miniscrew, orthopedic expansion of the midpalatal suture has become possible while minimizing dental side effects even in adults, and devices such as MARPE (Miniscrew-assisted Rapid Palatal Expansion) are being widely used.

Case presentation

A 26-year-old patient with the chief complaint of crooked teeth, multiple teeth missing. The patient exhibited Class II(Rt.) Class I(Lt.) canine relationship, severe crowding and root rest of upper lateral incisor, upper left second premolar, first and second molars, lower both second molars due to deep caries. All third molars were also observed crown fracture for the same reason. And the patient had poor oral hygiene.

Treatment results

The patient was achieved Class I relationship and favorable occlusion with dental implant restorations.

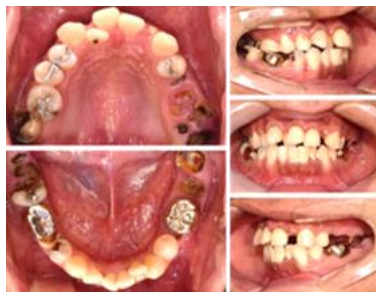

Fig. 1. pretreatment intra-oral photos.

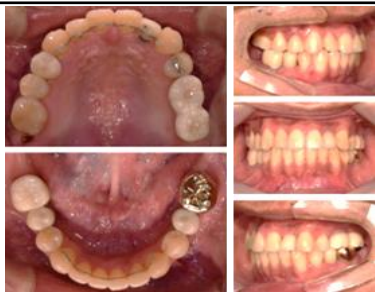

Fig. 3. posttreatment intra-oral photos.

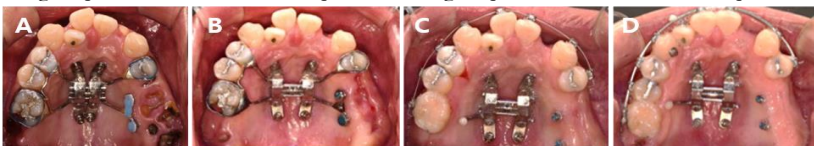


Fig. 2. Intra-oral photos of during treatment(Palatal Expansion using MARPE)

Conclusion

Horizontal discrepancy was improved using MARPE and appropriated results were also obtained in the vertical, sagittal aspects.